

Case Reports

Phil. J. Internal Medicine, 47: 83-87, March-April, 2009

PRIMARY EMPTY SELLA WITH PARTIAL HYPOPIUITARISM AND AUTOIMMUNE THYROIDITIS

Karla Kristine Silverio-Fernando, M.D.,* Frances Lina Lantion-Ang, M.D.**
and Cecilia A. Jimeno, M.D.***

ABSTRACT

Clinical Presentation: A 21-year-old female presented with primary amenorrhea, delayed puberty, continuous linear growth, and torticollis. She noted impaired memory and frequent respiratory infection.

Physical Findings: Patient presented with eunuchoidal habitus, torticollis, facial asymmetry, micrognathia, and hyperelastosis. Thyroid gland was normal in size. Breast and pubic hair were Tanner Stage 2. Neurologic exam was normal.

Laboratory Work-up: LH and FSH were low with estradiol at pre-pubertal level, suggesting hypogonadotropic hypogonadism. Prolactin was slightly elevated. Twenty four-hour urinary free cortisol and 8AM serum cortisol were low with low normal plasma ACTH, indicating secondary adrenal insufficiency. TSH was elevated with depressed FT4 and elevated anti-thyroglobulin, suggesting autoimmune thyroiditis. The following tests were normal: growth hormone, FBS and 2-hour OGTT. Patient had delayed bone age by the Greulich-Pyle method. Bone densitometry revealed osteoporosis. Patient had 46XX karyotype. Pelvic ultrasound revealed infantile uterus. Sellar MRI showed empty sella.

Diagnosis: The patient was diagnosed with Primary Empty Sella based on Cranial MRI findings of fluid-filled sella with no history of pituitary adenoma or surgery; with hypogonadotropic hypogonadism, secondary adrenal insufficiency, and autoimmune thyroiditis.

Treatment/Outcome: Sex hormone replacement was started, with improvement in breast size and commencement of regular menstrual cycles. Levothyroxine was started, with normalization of the TSH. Prednisone was given at 5mg/day. Alendronate was added for osteoporosis.

Significance: PES is rare, with 5.5% occurrence rate. Previous studies have reported preserved pituitary function in most cases. However, partial or total hypopituitarism has been described in 25% of patients, and hyperprolactinemia in 10%. The coexistence of autoimmune thyroiditis may support the possibility of an autoimmune mechanism behind the development of hypopituitarism in PES.

Recommendations: Full endocrine panel should be done in patients presenting with primary empty sella to screen for hormone deficiencies. Presence of autoantibodies should be determined since this syndrome may be linked to autoimmunity.

Keywords: Hypopituitarism, autoimmune thyroiditis, primary empty sella, primary amenorrhea

INTRODUCTION

Primary empty sella (PES) is defined as a cerebrospinal fluid-filled sella, with a small pituitary gland compressed to the rim of the fossa, in the absence of either other pathological processes or a history of previous pituitary surgery, radiotherapy or apoplexy.¹ It is a neuroradiological entity, most reliably confirmed by Magnetic Resonance Imaging (MRI). Most patients with PES are asymptomatic and have normal pituitary function tests, with the condition discovered as an incidental finding on imaging studies. However, reports from the recent decades have revealed that primary empty sella could be associated with hypopituitarism.²⁻⁸ While the etiology of PES is not completely clear, it is currently viewed as being related to the mechanical transmission of the cerebrospinal fluid pressure through an incomplete sellar diaphragm.¹ Recent case reports, however, suggest several other etiologies, one of which involves autoimmunity. We present a case of primary empty sella associated with partial hypopituitarism and primary hypothyroidism, in which an autoimmune mechanism may be involved in the pathophysiology and development of the disease.

Case

M.M., a 20-year old female, was referred to our institution for primary amenorrhea and lack of secondary sexual characteristics (breast and pubic hair development). The patient was born full-term

* Fellow, Section of Endocrinology, Diabetes and Metabolism, University of the Philippines-Philippine General Hospital

** Training Officer, Section of Endocrinology, Diabetes and Metabolism, University of the Philippines-Philippine General Hospital

*** Consultant, Section of Endocrinology, Diabetes and Metabolism, University of the Philippines-Philippine General Hospital

Reprint request to: Karla Kristine Silverio-Fernando, M.D., 53 Shanghai St., Better Living Subd., Parañaque City, Philippines

to a G10P9 mother, with no perinatal complications. Her parents did not notice any developmental delay, and she was able to go to regular school without academic difficulty. She eventually graduated from high school and proceeded to college but stopped due to frequent respiratory tract infections as well as poor memory and concentration. Past medical history revealed childhood Koch's infection and anemia which did not necessitate blood transfusion. There was no similar illness in the family.

When the patient was 18 years old, her family became concerned about her primary amenorrhea. There was concomitant delayed breast and pubic hair development. The patient was also noted to have continued increase in height even beyond the age of 18 years, accompanied by increase in shoe size and worsening torticollis. There was no note of seizures, loss of consciousness, or visual impairment. Her family decided to consult an obstetrician for the primary amenorrhea. Pelvic ultrasound revealed infantile uterus. Cranial CT scan done at that time was normal. She was eventually lost to follow up and came back only after 2 years. Sellar MRI done at 20 years old revealed an empty sella. (Fig.1) Patient was then referred to our institution.

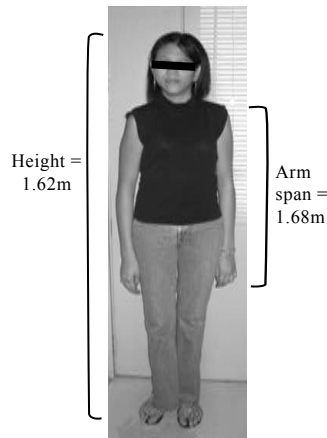


Fig. 2. Eunuchoid Habitus Showing Facial



Fig. 3. Close-up Shot Asymmetry

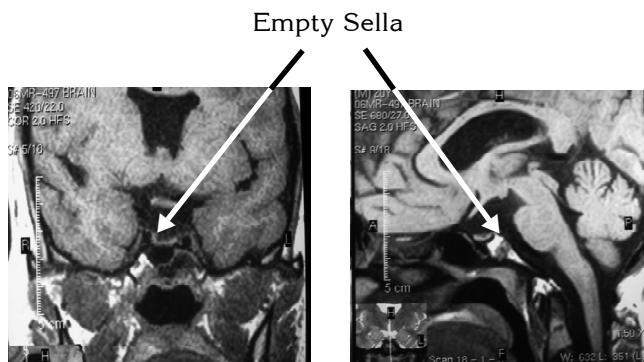


Fig. 1. Cranial MRI (A, Coronal Cut; B, Sagittal Cut). The Arrows Point to the Fluid-Filled Sella.

On physical examination, the patient was ambulatory with stable vital signs, intact immediate, recent, and distant memory and good judgment. She presented with kyphosis and a eunuchoidal habitus (Fig. 2), with a height of 1.62m and an arm span of 1.68m. She had marked right-sided torticollis accompanied by facial asymmetry, with a low-set ear and lower eyebrows and eyes on the left. (Fig. 3) The patient had micrognathia and hyperelastosis, and was noted to be flat-footed. Thyroid gland measured 2.5x4cm/lobe and was smooth and doughy. Breast and pubic hair development was graded as Tanner Stage 2. Neurologic exam was normal, except for decreased sense of smell on the left.

The results of the baseline endocrine tests are seen in Table I. 75-g OGTT was normal. Patient had delayed bone age (compatible with a 13- to 14-yr old female) by the Greulich-Pyle method. Bone densitometry revealed decrease age- and sex-matched bone density, with a spine Z-score of -1.8, femoral Z-score of -2.8, and radius Z-score of -2.6. Patient had 46XX karyotype. Repeat pelvic ultrasound revealed infantile uterus. Two-dimensional echocardiography (2D Echo) revealed normal sized left ventricle with adequate systolic function, mild mitral regurgitation, severe tricuspid regurgitation, and pulmonic regurgitation. The patient was referred to Ophthalmology, where she was assessed with posterior synechia, OS, probably post-inflammatory, and abnormal retinal correspondence. No active intervention for the ophthalmologic findings was recommended.

Table I. Baseline Endocrine Test Results

Test	Result	Comment
LH	1.98 mIU/mL	Low
FSH	2.15 mIU/mL	Low
Estradiol	33.4 g/mL	Pre-pubertal
Prolactin	24.9 ng/mL	Sl. Elevated
24H urine cortisol	2.9 ug/ 24 hrs	Low
8AM serum cortisol	22.1 nmol/L	Low
ACTH	6.37 pg/mL	Inappropriately normal
GH	4.4 ng/mL	Normal
FT4	5.9 pmol/L	Low
TSH	19 mIU/L	High
Anti-Tg	76 U/mL	High

The patient was therefore diagnosed with Primary Empty Sella based on the findings on sellar MRI of a fluid-filled sella, with no history of previous pituitary adenoma or surgery. She has associated partial

hypopituitarism, specifically hypogonadotropic hypogonadism and secondary adrenal insufficiency (ACTH deficiency), hyperprolactinemia, secondary osteoporosis, and autoimmune thyroiditis. She was started on sex hormone replacement, with note of improvement in breast size and menstrual cycle. Levo-thyroxine was started and maintained at 62.5ug/day, with normalization of the TSH. She was also given physiologic dose of Prednisone at 5mg/day. Alendronate was added to address the osteoporosis. The patient was referred to Orthopedic Surgery for the torticollis and the scoliosis. Resection of the sternocleidomastoid muscle was recommended to correct the torticollis and prevent further facial asymmetry, but the patient refused surgery and opted for non-surgical rehabilitative therapy. No surgery was recommended for the scoliosis, but patient was advised close follow-up at least until the physis has closed.

DISCUSSION

The term “empty sella” was originally proposed by Busch in 1951 to refer to the autopsy finding of a sella turcica only partially filled by the pituitary gland, which appeared flattened against the sellar floor, lateral walls, and dorsum sellae.⁹ Strictly speaking, it is a technically incorrect term, since the sella is actually not empty but is rather occupied by the pituitary gland, with its stalk, the arachnoid, CSF, and occasionally, the optic system and the third ventricle. Neuroradiographically, empty sella is identified when subarachnoid space is present below the diaphragmatic line, i.e. a line between the superior margin of the tuberculum sellae and the superior aspect of the dorsum sellae.⁵

Primary empty sella is not uncommon. It has been reported in a range between 5.5% and 23% in autopsy findings of the sellar area, and has been reported in 8-35% of the general population.¹⁰ With the advent of modern technology ushering in the widespread use of computed tomography (CT) and magnetic resonance imaging (MRI) techniques, PES has become a frequent incidental finding. It is more commonly seen among females, and is often associated with obesity, hypertension, headache, and nonspecific visual alterations.¹

Previous studies have reported preserved normal pituitary function in most PES cases, but recent case reports and case series have revealed significant occurrence of endocrine alterations. De Marinis *et al* reported 19% of their study population of 213 patients with PES as having documented endocrine

abnormalities. Among the endocrine alterations, hyperprolactinemia is the most frequent, seen in 11% of patients with PES, probably attributable to pituitary stalk compression caused by the remodeling of the hypothalamopituitary region and local altered CSF dynamics.⁹ In the study of De Marinis *et al*, basal endocrine evaluation demonstrated a tendency toward hyperprolactinemia in the entire female population, similar to our patient’s case.¹⁰

The compression of the pituitary gland and/or stalk can cause insufficient function of the gland. Global hypopituitarism was thought to be rare, occurring in about 2% of patients with PES. De Marinis *et al* reported that 4% of their cohort with PES was confirmed with anterior hypopituitarism. Isolated pituitary hormone deficiencies have been shown to occur slightly more frequently than panhypopituitarism. Growth hormone deficiency is the most frequent hormone deficiency described in PES,^{1,10} which is not surprising since the growth hormone is the most vulnerable pituitary hormone, with the somatotroph cells accounting for up to 50% of the normal pituitary gland volume. In about 6% of patients with PES, hypogonadotropic hypogonadism has been observed, either of hypothalamic or pituitary origin. Female patients with this deficiency usually present with primary amenorrhea, as seen in our patient. Isolated deficiencies of ACTH, TSH, and antidiuretic hormone have also been described, each in about 1% of patients. Our patient did not present with panhypopituitarism nor with isolated hormone deficiency, but rather with partial hypopituitarism, comprising of hypogonadotropic hypogonadism and ACTH deficiency. Although our patient’s baseline GH was normal and there was no feature of GH deficiency, it still cannot be totally ruled out since this is diagnosed by doing a stimulation test, such as the GHRH-arginine stimulation test.

Empty sella has been described in patients with other disorders involving the pituitary or hypothalamus, particularly in children and adolescents. These include diabetes insipidus and delayed or precocious puberty.⁵ Dallago *et al* also reported two cases of Kallmann syndrome associated with empty sella. These patients were females aged 20 and 29 years old, presenting with primary amenorrhea, prepubertal estradiol, and low gonadotropin levels.¹¹ Kallmann syndrome was actually considered in our patient, due to the presence of hypogonadotropic hypogonadism accompanied by a eunuchoid habitus, hyposmia, and midline defects (manifested as cardiac valvular lesions). However, our case was not consistent with isolated hypogonadotropic hypogonadism, since our patient was also found to be deficient of ACTH.

The mechanism that causes PES is unknown, but several theories have been proposed, including: (1) Normal anatomic variation (thus the symptoms are not related to the condition); (2) rupture of a pre-existing intra- or parasellar CSF cyst; (3) pituitary gland hypertrophy (as seen in pregnancy) and subsequent hypotrophy (as seen after menopause); (4) primary or secondary increase of intracranial pressure; and (5) presence of an incompetent or absent sellar diaphragm, which is the most widely accepted theory at present. An autoimmune mechanism has been recently proposed, mainly due to the emerging cases of empty sella associated with an autoimmune condition. Shirahama *et al* reported a case of a 66-year-old nulliparous woman with empty sella and hypopituitarism associated with rheumatoid arthritis.¹² Likewise, Otsuka *et al* reported a 33-year old woman with empty sella, severe adrenal insufficiency with impaired ACTH response, and central hypothyroidism. Both anti-pituitary and anti-thyroid autoantibodies were detected in the patient's serum, suggesting a strong autoimmune link.¹³ To further study on the role of autoimmunity, Komatsu *et al.* determined the frequency of detection of serum antibodies against pituitary cells in patients with primary empty sella syndrome. In their study, anti-corticotropin antibodies were found in 75%, while anti-prolactin antibodies were found in 47% of the patients with PES. Forty four percent of the patients had both antibodies. They were able to demonstrate that in patients with pituitary adenomas, the prevalence of antipituitary antibodies was significantly lower than in those with the empty sella syndrome.¹⁴ Contrary to this, however, the study of Bensing *et al* suggests that autoimmune mechanism may be of minor importance only in the pathophysiology of PES. In this study, eleven organ-specific autoantibodies were measured in serum to evaluate possible autoimmune components in the empty sella syndrome. They found that majority (18 out of 30, or 60%) of patients with PES exhibited no immunoreactivity at all, and none of the remaining 12 PES patients reacted against more than one autoantigen. Pituitary autoantibodies were also not correlated to the pituitary function or sellar size, although the results of this study indicated a tendency of increased autoimmunity in patients with hypopituitarism and normal sella size.¹⁵ Thus, although this shows that autoimmune components may only be of minor importance in patients with PES, selective cases, such as those with associated hypopituitarism, may still be the result of an autoimmune mechanism. Our case supports this theory, since the empty sella was associated with hypopituitarism and autoimmune thyroiditis.

A possible cause of hypopituitarism suggested in

patients with PES may be lymphocytic hypophysitis, which is also linked to autoimmunity since this condition involves dense infiltration of lymphocytes and plasma cells in the pituitary gland as well as presence of antipituitary antibodies. Not surprisingly therefore, lymphocytic hypophysitis is often associated with autoimmune disorders, including Hashimoto's thyroiditis, adrenalitis, parathyroiditis, and pernicious anemia. Almost all of the patients reported were women, and in the majority, the diagnosis of lymphocytic hypophysitis was usually made at autopsy or at transsphenoidal surgery during pregnancy.¹² Although it usually presents as an intrasellar or suprasellar mass, Lack reported a case of lymphocytic hypophysitis without a change in size of the pituitary gland or evidence of a pituitary mass.¹⁶ It may therefore be difficult to make an antemortem diagnosis of lymphocytic hypophysitis in a patient with no sign or symptom pointing to an intracranial mass, as in the case of our patient.

In primary empty sella syndrome, most patients suffer from central hypothyroidism as part of pituitary insufficiency. However, our patient presented with primary hypothyroidism with an autoimmune etiology. There have been a few other cases published with similar presentation. Milosevic *et al* reported 3 cases of empty sella with hypopituitarism but with primary hypothyroidism, two of which presented with elevated anti-TPO and anti-Tg antibody levels.¹⁷ In the cohort of De Marinis *et al*, autoimmune hypothyroidism was present in 3 patients with PES, while Del Monte *et al* saw 6 patients with primary thyroid dysfunction associated with thyroid autoimmunity. Again, these findings provide evidence for a possible link between autoimmunity and primary empty sella.

CONCLUSION

We have presented a case of primary empty sella syndrome in a young female presenting with partial hypopituitarism, made unique by the presence of primary hypothyroidism of autoimmune etiology. This illustrates one of the many possible manifestations of this syndrome, and also provides support to the emerging theory of a possible autoimmune involvement in its pathophysiology.

RECOMMENDATIONS

We recommend that full endocrine panel, including dynamic tests if necessary, be done for patients presenting with primary empty sella to screen for possible hormone deficiencies, since this syndrome may have variable findings. Antipituitary antibodies

and other autoantibodies should also be done to more firmly establish the link between the autoimmunity and the primary empty sella syndrome.

REFERENCES

1. Del Monte P, Foppiani L, Cafferata C, Marugo A, Bernasconi D: Primary "Empty Sella" in Adults: Endocrine Findings. *Endocrine Journal*, 53(6):803, 2006.
2. Shirahama M, Tegoshi S, Sugihara J, Nagasawa K, Niho Y: An Empty Sella Associated with Hypopituitarism in A Woman with Rheumatoid Arthritis. *Jpn J Med*, 28(2):207, 1989.
3. Brismar K, Efendic S: Pituitary Function in the Empty Sella Syndrome. *Neuroendocrinology*, 32:70, 1981.
4. Nakagawa H, Nagasaka A, Koie K, *et al*: Isolated Adrenocorticotropin Deficiency Associated with An Empty Sella. *J Clin Endocrinol Metab*, 55:795, 1982.
5. Cacciari E, Zucchini S, Ambrosetto P, *et al*: Empty Sella in Children and Adolescents with Possible Hypothalamic-Pituitary Disorders. *J Clin Endocrinol Metab*, 78(3):767, 1994.
6. Gallardo E, Schächter D, Cáceres E, *et al*: The Empty Sella: Results of Treatment in 76 Successive Cases and High Frequency of Endocrine and Neurologic Disturbances. *Clin Endocrinol (Oxf)*, 37(6):529, 1992.
7. Cannavò S, Curtò L, Venturino M, *et al*: Abnormalities of Hypothalamic-Pituitary-Thyroid Axis in Patients with Primary Empty Sella. *J Endocrinol Invest*, 265(3):236, 2002.
8. Durodoye OM, Mendlovic DB, Brenner RS, Morrow JS: Endocrine Disturbances in Empty Sella Syndrome: Case Reports and Review of Literature. *Endocr Pract*, 11(2):120, 2005.
9. Guinto G, Mercado M, Abdo M, *et al*: Primary Empty Sella Syndrome. *Contemporary Surgery*, 29(11):1, 2007.
10. De Marinis L, Bonadonna S, Bianchi A, Maira G, Giustina A: Extensive Clinical Experience: Primary Empty Sella. *J Clin Endocrinol Metab*, 90(9):5471, 2005.
11. Dallago CM, Abech DD, Pereira-Lima JF, Leães CG, Batista RL, Trarbach EB, Oliveira MD: Two Cases of Kallmann Syndrome Associated with Empty Sella. *Pituitary* 2007 May 26. [Epub ahead of print].
12. Shirahama M, Shizuko T, Sugihara J, Nagasawa K, Niho Y: An Empty Sella Associated with Hypopituitarism in A Woman with Rheumatoid Arthritis. *Jpn J Med*, 28(2):207, 1989.
13. Otsuka F, Ogura T, Hayakawa N, Harada S, Kageyama J, Makino H: Reversible Hypothyroidism in Empty Sella Syndrome: A Case Report. *Endocr J Jun*, 45(3):385, 1998.
14. Komatsu M, Kondo T, Yamauchi K, *et al*: Antipituitary Antibodies in Patients with the Primary Empty Sella Syndrome. *J Clin Endocrinol Metab*, 67(4):633, 1988.
15. Bensing S, Rorsman F, Crock P, *et al*: No Evidence for Autoimmunity As A Major Cause of the Empty Sella Syndrome. *Exp Clin Endocrinol Diabetes*, 112(5):23, 2004.
16. Lack EE: Lymphoid "Hypophysitis" with End Organ Insufficiency: *Arch Pathol*, 99:215, 1975.
17. Milosevi M, Stojanovi M, Nesovi M: Primary Hypothyroidism Associated with Empty Sella Turcica and Hypopituitarism]. *Med Pregl* 58(7-8):410, 2005.